

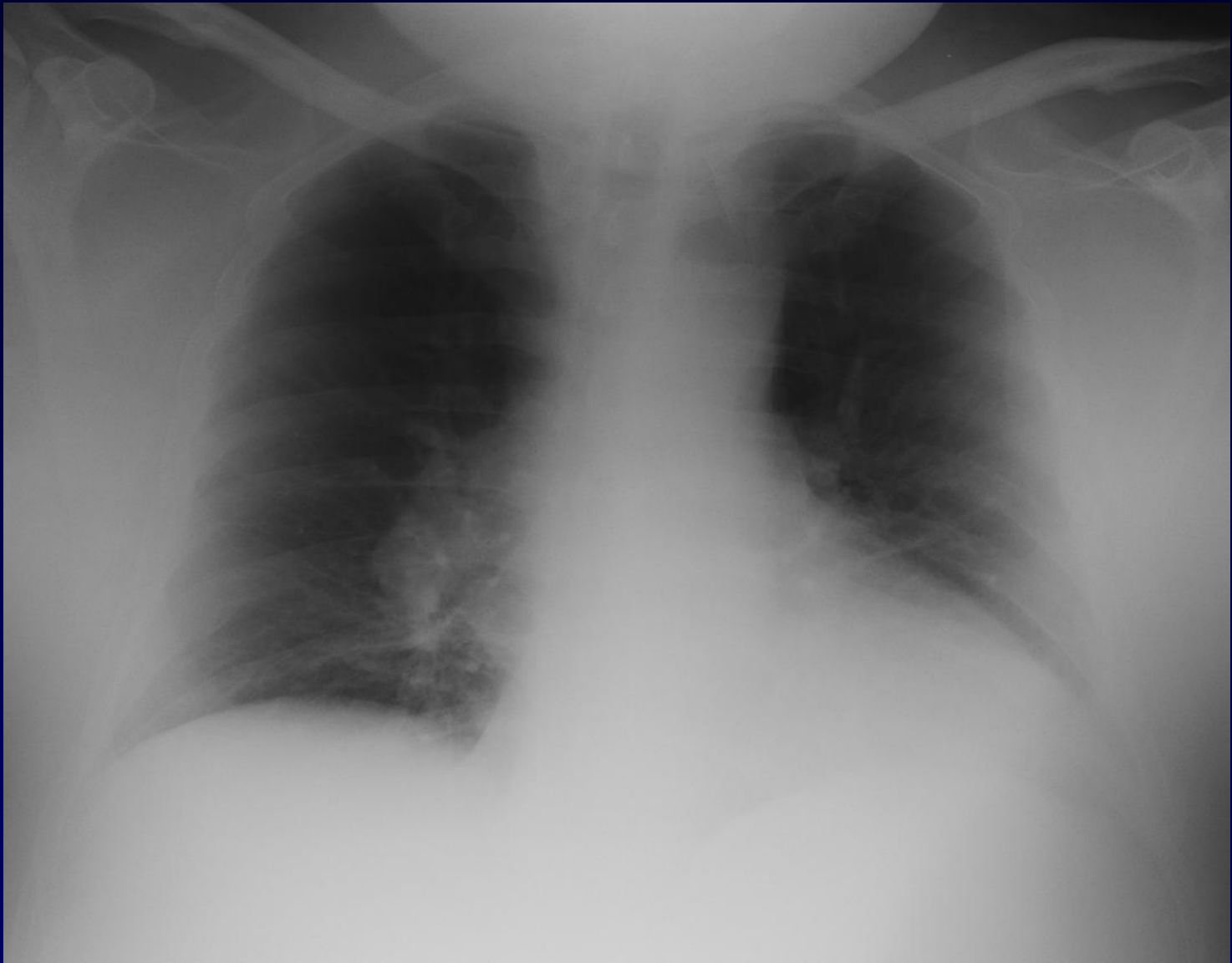


Dr LACOUT A

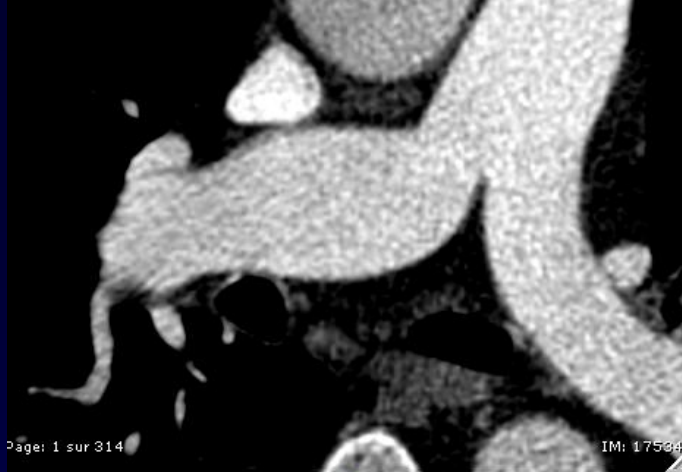
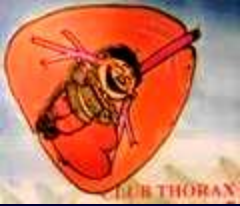Homme de 62 ans

Prothèse du genou gauche infectée

Dyspnée : EP ?

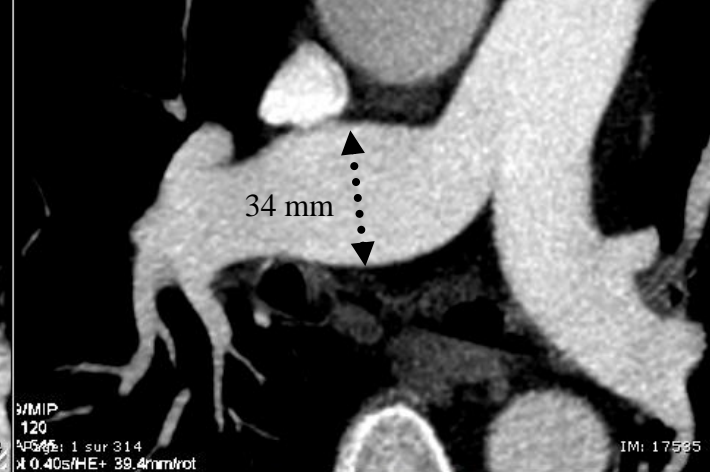

RT



Page: 1 sur 314

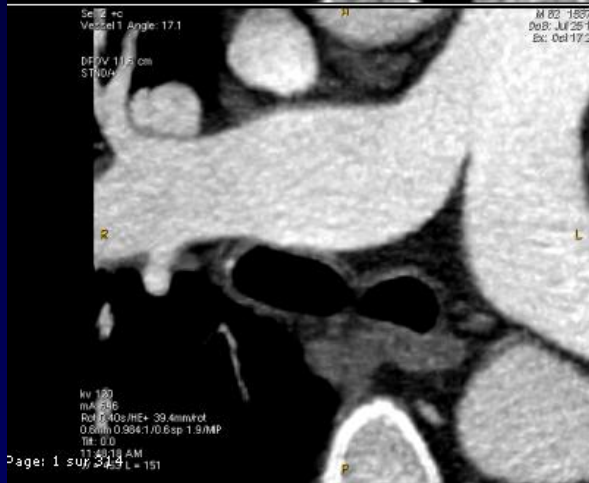IM: 17584



34 mm

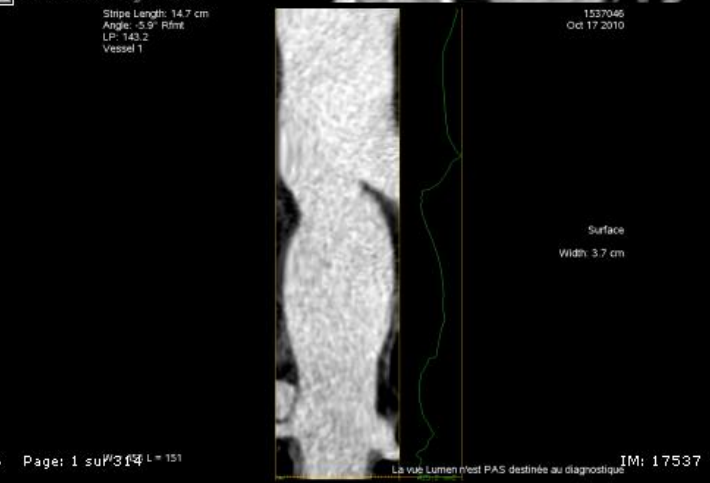
W/MIP  
120  
kVp: 1 sur 314  
k: 0.40s/HE+ 39.4mm/rot

IM: 17585



Page: 1 sur 314

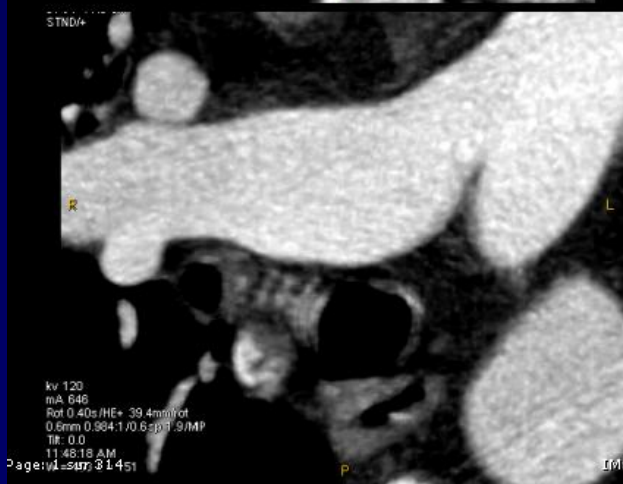IM: 17536



1537046  
Oct 17 2010

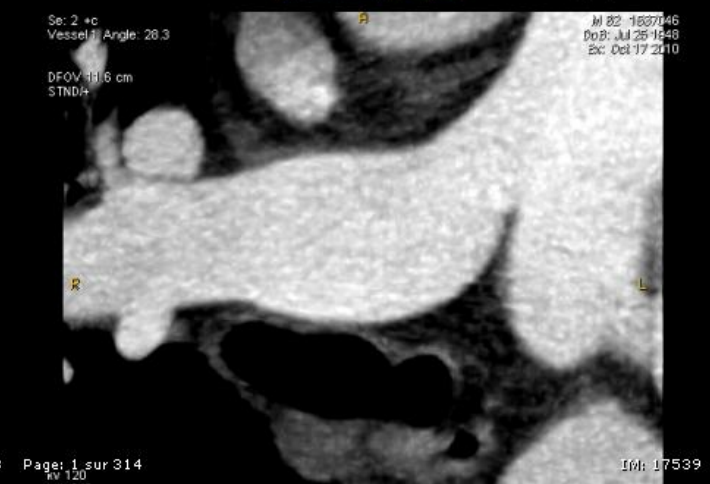Surface  
Width: 3.7 cm

IM: 17537



Page: 1 sur 314

IM: 17538



Page: 1 sur 314

IM: 17539

Se: 2 +c  
Vessel 1 Angle: 17.1  
DFOV: 111.6 cm  
STND: R

M 82-1637046  
DoB: Jul 26 1948  
Ex: Oct 17 2010

Stripe Length: 14.7 cm  
Angle: -5.9° Rinn  
LP: 143.2  
Vessel 1

kV: 120  
mA: 646  
Rot: 0.40s/HE+ 39.4mm/rot  
0.6mm 0.984:1/0.6sp:1.9/MIP  
Tilt: 0.0  
11:48:18 AM

La vue Lumen n'est PAS destinée au diagnostic

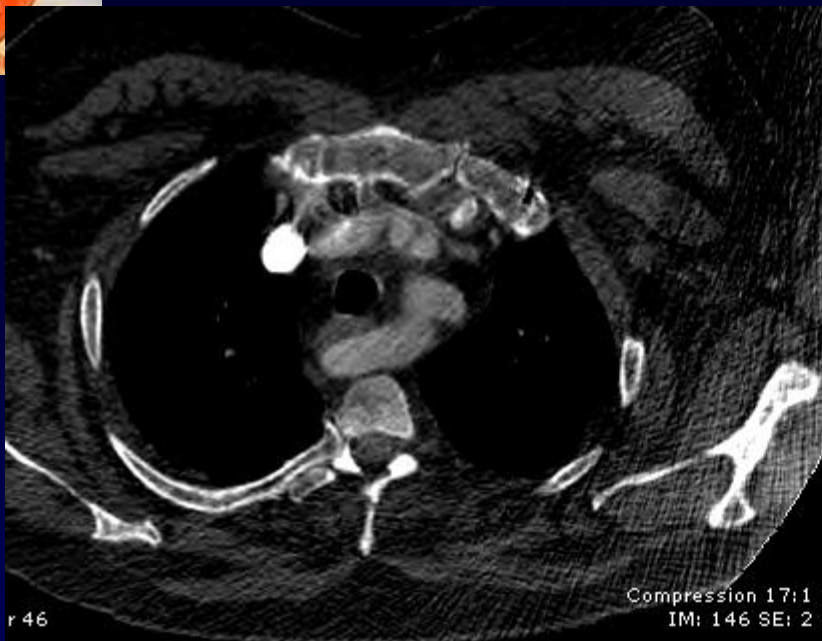
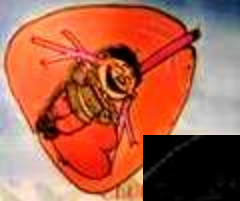
Page: 1 sur 314

Page: 1 sur 314

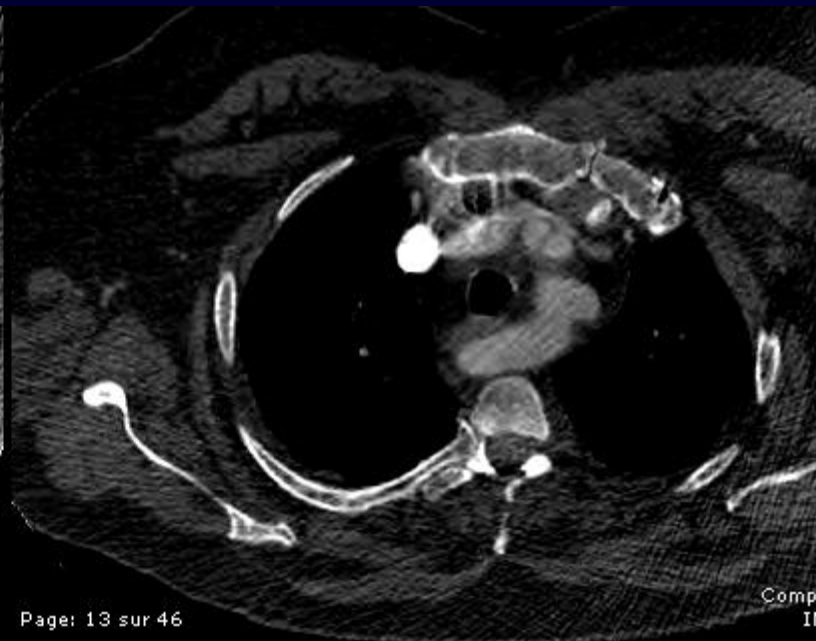kV: 120  
mA: 646  
Rot: 0.40s/HE+ 39.4mm/rot  
0.6mm 0.984:1/0.6sp:1.9/MIP  
Tilt: 0.0  
11:48:18 AM

Se: 2 +c  
Vessel 1 Angle: 28.3  
DFOV: 111.6 cm  
STND: R

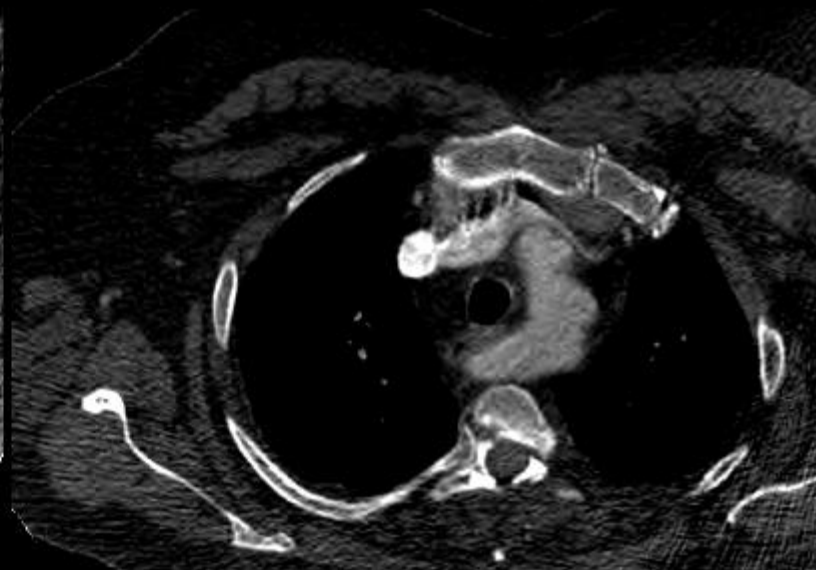
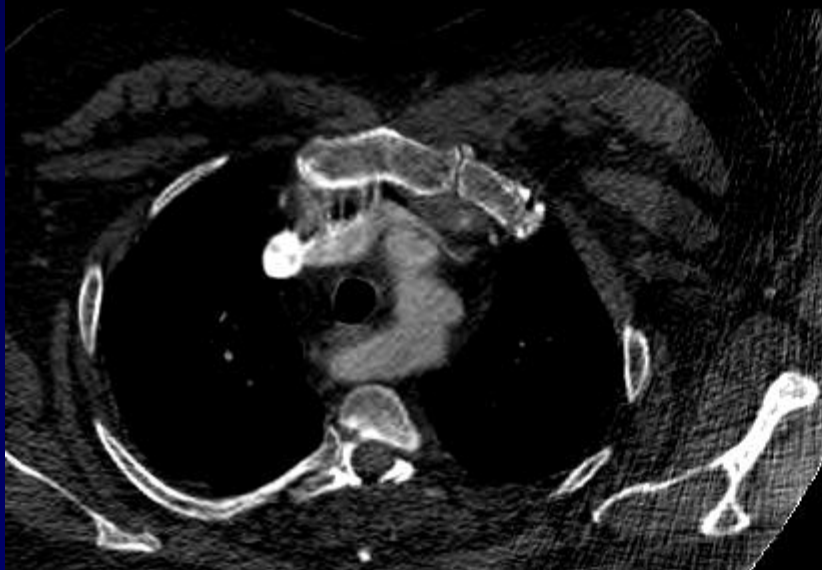
M 82-1637046  
DoB: Jul 26 1948  
Ex: Oct 17 2010



Compression 17:1  
IM: 146 SE: 2



Comp  
IM



r 46

Page: 13 sur 46



# Diagnostic ?

Anévrisme de l'Artère Pulmonaire Droite

Lusoria

M

Reformatted A.  
MPVR, 200,0 mm

R

